



## The human vomeronasal organ and pheromonal communication: facts and fantasy

By ANGELA WÖHRMANN-REPENNING

*Zoology and Comparative Anatomy, University of Kassel, Kassel*

*Receipt of Ms. 25. 05. 2000*

*Acceptance of Ms. 25. 07. 2000*

**Key words:** Vomeronasal organ, humans, mammals, pheromonal communication

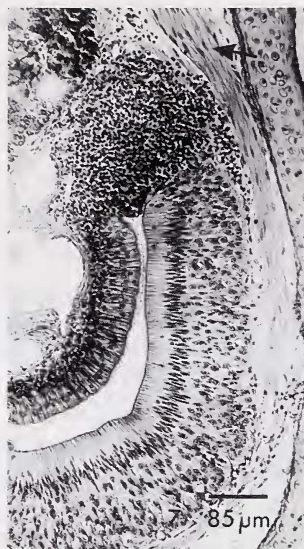
Since the results of some recent studies (MONTI-BLOCH and GROSSER 1991; BERLINER et al. 1996) have suggested a functioning vomeronasal organ (VNO) in humans, this topic has drawn much attention. Its involvement in human pheromonal communication is suggested (WELLER 1998) and the presence of a well established VNO is almost euphorically postulated. These sort of studies seem to indicate that our VNO never went rudimentary and instead continues to work at a subconscious level.

Some critical remarks on this subject are in order. By comparing the findings in humans (MORAN et al. 1991; SMITH et al. 1997; TAKAMI et al. 1993) with own results on the VNO in a large number of different mammals (WÖHRMANN-REPENNING 1984) the suggestions of all previous anatomists have been verified: This accessory olfactory organ has indeed gone rudimentary in the line of catarrhine primates, including man (FRETS 1914; KOLMER 1927; MAIER 1997). Numerous criteria can be used to illustrate this fact.

It has been well established for a long time that the VNO in humans is always present in the fetus. It shows the greatest differentiation in early embryonic stages and quickly decreases during further development (BOEHM and GASSER 1993; STARCK 1975). It is for the most part – but not always (!) – present in adult humans as small bilateral pits at the nasal septum (MORAN et al. 1991; KOLMER 1927). But in most other mammals, which also includes prosimian and platyrrhine primates (BERGMANN 1997), the VNO does rapidly grow during ontogeny increasing in size and in the complexity of its histological structure (WÖHRMANN-REPENNING and BARTH-MÜLLER 1994) (Fig. 1).

The VNO in most mammals is closely associated to an autonomous intranasal system with a complicated morphology, called the vomeronasal complex (VNC) (WÖHRMANN-REPENNING 1993). Its special anatomy guarantees the functioning of the blind ending, tube-shaped VNO. Humans definitely do not have anything comparable to a VNC. Moreover their VNO has even lost contact with the paraseptal cartilage, which normally surrounds the VNO and near its rostral opening transforms into an intricate structure, often by fusing with other cartilages. In humans the VNO is situated in an unusual position, quite a way above the septal base where the cartilage itself actually has retained its ancestral site.

The vomeronasal nerve normally serves the epithelium of the VNO and connects it with the accessory olfactory bulb (AOB). The VN-nerve bundles are remarkably voluminous and they follow the olfactory epithelial layer of the VNO (Fig. 1). In humans a thorough tracing (STENSAAS et al. 1991) is necessary to identify potential vomeronasal axons in the area surrounding the organ. An AOB is present only during early embryonic development, later it quickly regresses and is completely absent in adults (HUMPHREY 1940). The same situation has been reported for catarrhine primates and in general for all vertebrates lacking a VNO (HUMPHREY 1940; STEPHAN 1967; STEPHAN et al. 1982).



**Fig. 1.** Cross-section of the VNO of *Tupaia glis*. Note the thick olfactory epithelium, the VN-nerve (arrow) and the vein plexus at the left side. 10  $\mu$ m. Azan.

All recent studies on the human VNO postulate its involvement in putative pheromone detection (MONTI-BLOCH and GROSSER 1991; BERLINER et al. 1996; WELLER 1998). The pheromones may reach the organ as airborne substances both under normal (STERN and McCCLINTOCK 1998) and artificial conditions (MONTI-BLOCH and GROSSER 1991; BERLINER et al. 1996). In other mammals the complicated anatomical situation of the VNC guarantees that the olfactory stimuli provided for the VNO are non-volatile molecules (WYSOCKI et al. 1980) which, suspended in liquid, enter the VNO by means of a vasomotorically induced sucking- and pumping mechanism (WÖHRMANN-REPENNING 1991). It is suggested that the stimulation of the human VNO takes place on subconscious level. Several behavioral patterns in other mammals indicate that particular attention is given to substances which stimulate the VNO (BAILEY 1978; MELESE-D'HOSPITAL and HART 1985) and that the VNO, which plays an important role in social and sexual situations (ESTES 1972) and food detection processes (COOPER and BHATNAGAR 1976) does not work very selectively (MEREDITH et al. 1980).

Thus, we should accept that the VNO in humans definitely has gone rudimentary. If it really has retained some form of remnant function, pheromones are carried to it during inhalation. This, however, would generally impede experimental work with humans, because volatile substances are able to reach every receptor cell within the nasal cavity. In addition it seems quite contradictory that a noteworthy percentage of adult humans actually lack the VNO completely without revealing significant sensory deficits. In this sense it is also surprising that during endonasal surgery the patient's VNO can be experimentally removed without any apparent negative effects (GAAFAR et al. 1998).

## References

- BAILEY, K. (1978): Flehmen in the ring-tailed lemur (*Lemur catta*). Behaviour **65**, 309–319.
- BERGMANN, M. (1997): Eine vergleichend anatomische Studie über den Vomeronasalkomplex der Primates. Diss. thesis, Univ. of Kassel, Germany.
- BERLINER, D. L.; MONTI-BLOCH, L.; JENNINGS-WHITE, C.; DIAS SANCHEZ, V. (1996): The functionality of the human vomeronasal organ (VNO): Evidence for steroid receptors. J. Steroid Biochem. Molec. Biol. **58**, 259–265.

- BOEHM, N.; GASSER, B. (1993): Sensory receptor-like cells in the human foetal vomeronasal organ. *NeuroReport* **4**, 867–870.
- COOPER, J. G.; BHATNAGAR, K. P. (1976): Comparative anatomy of the vomeronasal organ complex in bats. *J. Anat.* **122**, 571–601.
- ESTES, R. D. (1972): The role of the vomeronasal organ in mammalian reproduction. *Mammalia* **36**, 315–341.
- FRETS, G. P. (1914): Beiträge zur vergleichenden Anatomie und Embryologie der Nase der Primaten. *Morph. Jb.* **48**, 239–279.
- GAAFAAR, H. A.; TANTAWY, A. A.; MELIS, A. A.; HENNAWY, D. M.; SHEHATA, H. M. (1998): The vomeronasal (Jacobson's) organ in adult humans: Frequency of occurrence and enzymatic study. *Acta Otolaryngologica* **118**, 409–412.
- HUMPHREY, T. J. (1940): The development of the olfactory and the accessory olfactory formations in human embryos and fetuses. *J. Comp. Neurol.* **73**, 431–468.
- KOLMER, W. (1927): Das Geruchsorgan. In: *Handbuch der mikroskopischen Anatomie des Menschen*. Ed. by W. v. Möllendorff. Berlin: Springer Verlag. Pp. 192–249.
- MAIER, W. (1997): The nasopalatine duct and the nasal floor cartilages in catarrhine primates. *Z. Morph. Anthropol.* **81**, 289–300.
- MELESE-D'HOSPITAL, P. Y.; HART, B. L. (1985): Vomeronasal organ cannulation in male goats: Evidence for transport of fluid from oral cavity to vomeronasal organ during flehmen. *Physiol. Behav.* **35**, 941–944.
- MEREDITH, M.; MARQUES, D. M.; O'CONNELL, R. J.; STERN, F. L. (1980): Vomeronasal pump: Significance for male hamster sexual behavior. *Science* **207**, 1224–1226.
- MONTI-BLOCH, L.; GROSSER, B. I. (1991): Effect of putative pheromones on the electrical activity of the human vomeronasal organ and the olfactory epithelium. *J. Steroid Biochem. Molec. Biol.* **39**, 573–582.
- MORAN, D. T.; JAFEK, B. W.; ROWLEY, J. C. (1991): The vomeronasal (Jacobson's) organ in man: Ultrastructure and frequency of occurrence. *J. Steroid Biochem. Molec. Biol.* **39**, 545–552.
- SMITH, T. D.; SIEGEL, M. I.; MOONEY, M. P.; BURDI, A. R.; BURROWS, A. M.; TODHUNTER, J. S. (1997): Prenatal growth of the human vomeronasal organ. *Anat. Rec.* **248**, 447–455.
- STARCK, D. (1975): *Embryologie*. 3. Aufl. Stuttgart: Thieme Verlag.
- STENSAAS, L. J.; LAVKER, R. M.; MONTI-BLOCH, L.; GROSSER, B. I.; BERLINER, D. L. (1991): Ultrastructure of the human vomeronasal organ. *J. Steroid Biochem. Molec. Biol.* **39**, 553–560.
- STEPHAN, H. (1967): Quantitative Vergleiche zur phylogenetischen Entwicklung des Gehirns der Primaten mit Hilfe von Progressionsindices. *Mitt. Max-Planck-Ges.* **2**, 63–86.
- STEPHAN, H.; BARON, G.; FRAHM, H. D. (1982): Comparison of brain structure volumes in Insectivora and Primates. II. Accessory olfactory bulb (AOB). *J. Hirnforsch.* **23**, 575–591.
- STERN, K.; MCCLINTOCK, M. K. (1998): Regulation of ovulation by human pheromones. *Nature* **392**, 177–179.
- TAKAMI, S.; GETCHELL, M. L.; CHEN, Y.; MONTI-BLOCH, L.; BERLINER, D. L.; STENSAAS, L. J.; GETCHELL, T. V. (1993): Vomeronasal epithelial cells of the adult human express neuron-specific molecules. *NeuroReport* **4**, 375–378.
- WELLER, A. (1998): Communication through body odor. *Nature* **392**, 126–127.
- WÖHRMANN-REPENNING, A. (1984): Vergleichend anatomische Untersuchungen am Vomeronasalkomplex und am rostralen Gaumen verschiedener Mammalia. *Gegenbaurs morph. Jb.* **130**, 501–530, 609–637.
- WÖHRMANN-REPENNING, A. (1991): Functional aspects of the vomeronasal complex in mammals. *Zool. Jb. Anat.* **121**, 71–80.
- WÖHRMANN-REPENNING, A. (1993): The vomeronasal complex – A dual sensory system for olfaction and taste. *Zool. Jb. Anat.* **123**, 337–345.
- WÖHRMANN-REPENNING, A.; BARTH-MÜLLER, U. (1994): Functional anatomy of the vomeronasal complex in the embryonic development of the pig (*Sus scrofa* f. dom.). *Acta Theriol.* **39**, 313–323.
- WYSOCKI, C. J.; WELLINGTON, J. L.; BEAUCHAMP, G. K. (1980): Access of urinary nonvolatiles to the mammalian vomeronasal organ. *Science* **207**, 781–783.

**Author's address:** Prof. Dr. ANGELA WÖHRMANN-REPENNING, Zoology and Comparative Anatomy, University of Kassel, Heinrich-Plett-Str. 40, D-34132 Kassel, Germany. (E-mail: woehrep@hrz.uni-kassel.de)